



**PATIENT**

Patch Perez

**PRESENTING CLINICAL SIGNS**

History: Presented for annual PE on 4/1/22. Lung sounds are busy. No heart murmur. Suspect aspiration pneumonia. Submandibular nodes are enlarged.

**SPECIES**

Canine

**RADIOGRAPHIC FINDINGS** \*NOTE: Images submitted for supplemental cardiac information only. Mild cardiomegaly. No obvious evidence of CHF.

**BREED**

Havanese

**ELECTROCARDIOGRAPHIC FINDINGS** \*Note: Single lead ECGs are evaluated as a rhythm strip. Morphology/MEA cannot be definitively commented on.

A single lead ECG is available; 25mm/s, 10mm/mV. The average heart rate is 100bpm (range 78-107bpm). P waves are difficult to identify throughout; however, a sinus origin is suspected. P for every QRS complex and vice versa. The P and QRS morphologies are positive. No ectopic beats, pauses or other dysrhythmias observed.

ECG diagnosis: Normal sinus rhythm with respiratory variation.

**SEX**

Male Neutered

**ECHOCARDIOGRAM FINDINGS**

2D, m-mode, color flow and doppler imaging is available. Diffuse thickening of mitral valve leaflets (anterior>posterior) with minimal prolapse into the left atrial lumen. Moderate eccentric mitral regurgitation with moderate left atrial dilation. Normal MR velocity. Borderline LV dilation with adequate myocardial function. The tricuspid valve appears subjectively normal, with trace tricuspid regurgitation. Normal velocity. Normal right atrial and ventricular diameter. The pulmonic and aortic valves are normal in morphology and mobility. Normal pulmonic and aortic outflow velocities. Mild aortic and trace pulmonic insufficiency. No pericardial or pleural effusion noted. No cardiac tumors observed.

**AGE**

10 years

**WEIGHT**

21.7lbs

**CARDIAC CHART**

**INTERPRETED BY**

Maggie Machen Lamy,  
DVM, DACVIM  
(Cardiology)

| CANINE CARDIAC PARAMETERS   | MR VMAX (m/s) | TR VMAX (m/s) | LA/AO (Boon method) | LA/AO (Heart Base; Swe) | FS (%)                          | EF (%)                                   | EPSS (cm)                                |
|---|---------------|---------------|---------------------|-------------------------|---------------------------------|--|--|
| NORMAL PARAMETER  | 4.5-5.5       | <2.7          | 1.3                 | <1.6                    | 28-40                           | 40-100                                   | <0.6                                     |
| PATIENT   | 5.9           | 2.2           | 1.6                 | 1.7                     | 53                              | 85                                       | 0.3                                      |
| CANINE CARDIAC PARAMETERS   | HR (BPM)      | AV VMAX (m/s) | PV MAX (m/s)        | BODY WEIGHT (kg)        | LA 2D short axis Base view (cm) | LVIDd Avg; 2D and m-mode short axis (cm) | LVIDs Avg; 2D and m-mode short axis (cm) |
| NORMAL PARAMETER  | 50-100        | 0.7-1.7       | 0.7-1.6             | BELOW                   | BELOW                           | BELOW                                    | BELOW                                    |
| PATIENT   | 97            | 1.3           | 0.9                 | 9.8                     | 2.8                             | 3.3                                      | 1.7                                      |
| *Normal chamber parameters expressed as a mean value (SD)   |               |               |                     | 3                       | 1.27 (5.3)                      | 2.46 (2.46)                              | 1.36 (5.5)                               |
| <b>BODY WEIGHT DEPENDENT PARAMETERS</b>   |               |               |                     | 5                       | 1.40 (4.5)                      | 2.74 (5.2)                               | 1.60 (4.7)                               |
| <i>*Note: All measurements based upon multi-modal images and methods. An average value is reported.</i> |               |               |                     | 10                      | 1.50 (3.8)                      | 3.27 (3.5)                               | 2.06 (3.1)                               |
|   |               |               |                     | 15                      | 1.83 (2.0)                      | 3.71 (2.4)                               | 2.43 (2.1)                               |
|   |               |               |                     | 20                      | 2.02 (1.9)                      | 4.14 (2.2)                               | 2.80 (2.0)                               |
|   |               |               |                     | 25                      | 2.18 (2.4)                      | 4.48 (2.9)                               | 3.10 (2.5)                               |
|   |               |               |                     | 30                      | 2.33 (3.3)                      | 4.83 (3.9)                               | 3.39 (3.4)                               |
|   |               |               |                     | 35                      | 2.48 (4.3)                      | 5.17 (5.0)                               | 3.69 (4.5)                               |
|   |               |               |                     | 40                      | 2.62 (5.2)                      | 5.48 (6.1)                               | 3.96 (5.4)                               |
|   |               |               |                     | 50                      | 2.88 (7.1)                      | 6.07 (8.3)                               | 4.46 (7.4)                               |

Adapted from June Boon, Veterinary Echocardiography, 1998  
Rishniw M and Hollis NE, J Vet Intern Med 2000; 14:429-435  
Hansson et al, Vet Rad and Ultrasound 2002  
Bonagura et al. Echocardiography: principles of interpretation, Vet Clin North Am 15:1177, 1995

**IMAGING PERFORMED BY**

Kim Liedberg

**HOSPITAL NAME**

SVS Imaging WI

**REFERRING VET**

Dr. Beyer

**INVOICE**

23723

**DATE**

4/18/22

**PATIENT**

Patch Perez

**SPECIES**

Canine

**BREED**

Havanese

**SEX**

Male Neutered

**AGE**

10 years

**WEIGHT**

21.7lbs

**INTERPRETED BY**Maggie Machen Lamy,  
DVM, DACVIM  
(Cardiology)**IMAGING PERFORMED BY**

Kim Liedberg

**HOSPITAL NAME**

SVS Imaging WI

**REFERRING VET**

Dr. Beyer

**INVOICE**

23723

**DATE**

4/18/22

**INTERPRETATION OF THE FINDINGS & FURTHER RECOMMENDATIONS**

Chronic degenerative valve disease causing moderate mitral and trace tricuspid regurgitation. Moderate left atrial enlargement indicates there is relatively low risk for imminent complication, however risk for progression to spontaneous congestive heart failure in the future is elevated. An aortic leak is noted, and a baseline blood pressure is strongly recommended. No additional issues are identified. The ECG is unremarkable with a normal sinus rhythm.

Given the risk for progression and results of the EPIC trial, Pimobendan is indicated in this patient as below. Assessment of progression in the future will help predict long term outcome, however prognosis is guarded at this stage (B2).

While mainstem bronchi compression may certainly be contributing to a chronic increase in coughing, other primary airway contributions should also be considered (tracheal collapse, COPD/chronic bronchitis, etc.). Consider hydrocodone for any mechanical component due to cardiomegaly. Screening chest radiographs are recommended.

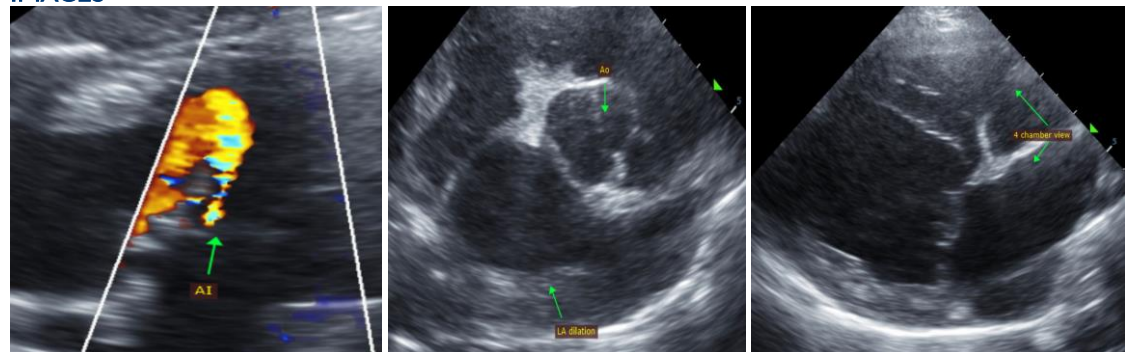
Omega fatty acid supplementation and mild salt restriction may also be of some long-term benefit. Monitor for development of a progressive cough, labored breathing, exercise intolerance or collapse episodes.

Once on the medication for 3-5 days, anesthetic risk is considered mildly elevated. Cardiac protective drug choices (opioid/benzodiazepine premedication, Propofol or alfaxalone induction, iso or sevo gas) are recommended. Monitor for arrhythmias, hypotension, and hypoxia both intra and post-operatively and intervene as necessary. Judicious IV fluid rates are recommended to avoid fluid overload. Avoid heart rate stimulating drugs such as atropine unless clinically indicated.

**PLAN**

Baseline BP is recommended. Institute heart muscle support Pimobendan 0.3mg/kg PO q12h. Consider hydrocodone as discussed.

Recommend monitor for progression with a recheck echocardiogram in 6 months, sooner if any development of clinical signs.

**IMAGES**

**IMAGING PERFORMED BY**

svsmobileimaging.com 309 - 737 - 3070



**Clinical Sonography & Telectology**

EDUCATIONAL TELECONSULTATION SERVICES™

1-800-838-4268 info@sonopath.com SonoPath.com

**PATIENT**

Patch Perez

**SPECIES**

Canine

**BREED**

Havanese

**SEX**

Male Neutered

**AGE**

10 years

**WEIGHT**

21.7lbs

**INTERPRETED BY**

Maggie Machen Lamy,  
DVM, DACVIM  
(Cardiology)

**IMAGING PERFORMED BY**

Kim Liedberg

**HOSPITAL NAME**

SVS Imaging WI

**REFERRING VET**

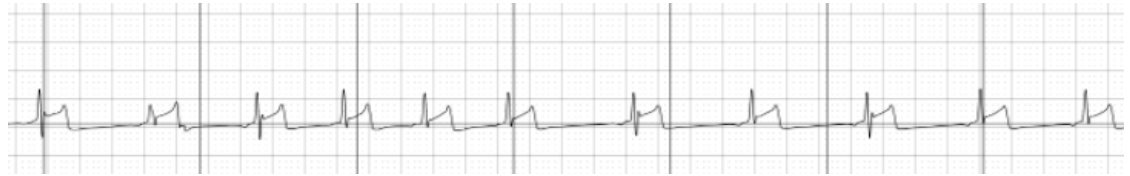
Dr. Beyer

**INVOICE**

23723

**DATE**

4/18/22



The information and recommendations provided are based on the images presented by the referring veterinarian. No evaluation can be communicated regarding pathology that was not visible in the image/video clips provided.

Thank you for this referral. If the clinical or image interpretation does not parallel your findings or if I can be of any further assistance, please contact me.

Maggie Machen Lamy, DVM  
Diplomate of the American College of Veterinary Internal Medicine (Cardiology)  
info@sonopath.com